Clinical Physiologist

Section Editor: John W. Kreit, M.D.

Positive End-Expiratory Pressure

When More May Not Be Better

Başak Çoruh[1] and Andrew M. Luks[1]

[1]Division of Pulmonary and Critical Care Medicine, University of Washington, Seattle, Washington

In Brief

A 52-year-old woman was admitted to the intensive care unit with severe lobar pneumonia and septic shock. She remained hypoxemic despite intubation, a high fraction of inspired oxygen, and positive end-expiratory pressure (PEEP). When PEEP was increased further, she paradoxically became more hypoxemic and her blood pressure and central venous hemoglobin saturation fell. These problems resolved after an intervention that derived from an understanding of the physiological principles of PEEP.

The Clinical Challenge

A 52-year-old woman with a history of polysubstance abuse presented with 2 days of dyspnea and malaise. In the emergency department, she had a temperature of 38.2°C, blood pressure of 109/52 mm Hg, heart rate of 125 beats per minute, and respiratory rate of 42 breaths per minute. Her initial hemoglobin saturation, using pulse oximetry (Sp_{O_2}), was 69% while breathing ambient air and improved to only 79% with the application of a nonrebreather mask. The patient was speaking in three- or four-word sentences and using accessory muscles of respiration. She had dry mucous membranes, left-sided crackles on lung auscultation, and warm distal extremities. Laboratory studies revealed severe lactic acidosis, acute kidney injury, and leukopenia. A chest radiograph demonstrated dense left lower lobe opacification consistent with pneumonia (Figure 1). She was promptly intubated for hypoxemic respiratory failure.

During the initial resuscitation, she received 6 L of isotonic saline and was started on norepinephrine and vasopressin infusions for refractory hypotension. Broad-spectrum antibiotics were administered. She was placed on volume assist-control ventilation with a set rate of 20 breaths per minute and a tidal volume of 450 ml (8 ml/kg ideal body weight). Despite receiving an inspired fractional oxygen concentration ($F_{I_{O_2}}$) of 1.0, and PEEP of 10 cm H_2O, the patient's Sp_{O_2} was only 90%. PEEP was subsequently increased to 20 cm H_2O after which the Sp_{O_2} decreased to 79%. This was accompanied by worsening hypotension and a decrease in the central venous hemoglobin saturation (Scv_{O_2}) from 60 to 40%.

Questions

1. What is the mechanism by which PEEP usually improves arterial hypoxemia?

2. Why did high levels of PEEP worsen arterial hypoxemia and decrease blood pressure and Scv_{O_2} in this patient?

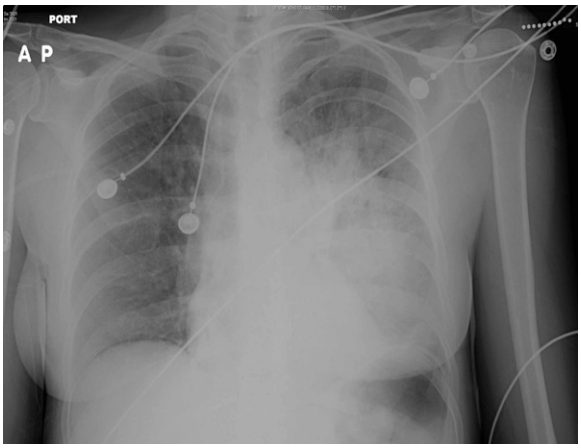

Figure 1. Admission chest radiograph demonstrating a dense left lower lobe opacity.

(Received in original form April 8, 2014; accepted in final form July 23, 2014)

Correspondence and requests for reprints should be addressed to Andrew M. Luks, M.D., Division of Pulmonary and Critical Care Medicine, Harborview Medical Center, 325 Ninth Avenue, Box 359762, Seattle, WA 98104. E-mail: aluks@u.washington.edu

Ann Am Thorac Soc Vol 11, No 8, pp 1327–1331, Oct 2014
Copyright © 2014 by the American Thoracic Society
DOI: 10.1513/AnnalsATS.201404-151CC
Internet address: www.atsjournals.org

Clinical Reasoning

Alveolar filling diseases, such as pneumonia and acute respiratory distress syndrome (ARDS), cause significant gas exchange abnormalities and, in particular, right-to-left intrapulmonary shunt. When a significant fraction of the cardiac output passes through unventilated alveoli (the shunt fraction), the Pa_{O_2} does not improve significantly with application of increased FI_{O_2} and other strategies are necessary to correct arterial hypoxemia. The most commonly used initial tactic in such situations is to increase PEEP. When used in diffuse alveolar filling processes such as ARDS, PEEP reduces the shunt fraction and improves Pa_{O_2} by increasing lung volume and opening or "recruiting" atelectatic alveoli. When used in focal processes, such as lobar pneumonia, however, PEEP can paradoxically worsen oxygenation by two mechanisms. First, increased PEEP causes overdistention of normal alveoli in regions not affected by the focal process. This causes an increase in capillary resistance in those regions, which redistributes blood flow to other regions, thereby worsening ventilation–perfusion ratios and arterial hypoxemia. Second, PEEP increases intrathoracic pressure, particularly when used in focal processes. This decreases venous return and cardiac output with subsequent adverse effects on systemic blood pressure and tissue oxygen delivery. When oxygen delivery decreases, tissue oxygen extraction increases, leading to a fall in central and mixed venous oxygen content and saturation, which, in the presence of significant shunt, further worsens arterial oxygenation.

The Clinical Solution

Dobutamine was initiated in response to the decrease in Scv_{O_2} and hypotension. The PEEP was then decreased back to 5 cm H_2O and the Sp_{O_2} improved to 95% over a period of 30 minutes. Her blood pressure and Scv_{O_2} also improved and the dobutamine was eventually stopped. Four days later, the patient developed worsening hypoxemia, at which time chest radiography revealed diffuse bilateral opacities. The PEEP was increased to 14 cm H_2O with subsequent improvement in her oxygenation but no effect on blood pressure or Scv_{O_2}.

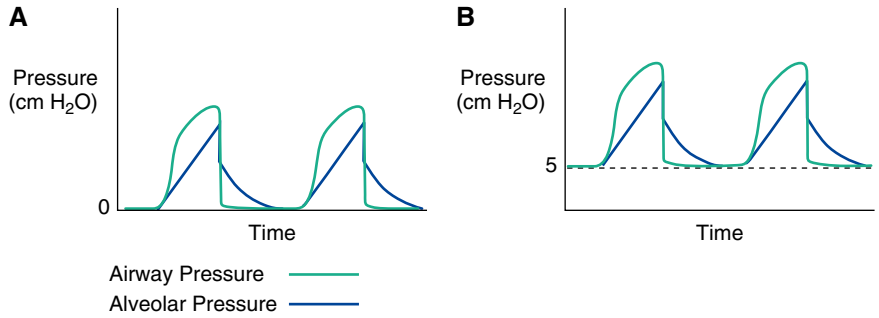

Figure 2. Airway (Paw, *teal line*) and alveolar (Palv, *blue line*) pressure in a mechanically ventilated patient (*A*) before and (*B*) after the addition of positive end-expiratory pressure (PEEP). PEEP increases Paw and Palv throughout the respiratory cycle.

The Science behind the Solution

The Beneficial Effects of PEEP

PEEP refers to the application of positive pressure during the expiratory phase of the respiratory cycle in patients receiving mechanical ventilation. Application of pressure in this manner leads to an increase in airway and alveolar pressure throughout the respiratory cycle (Figures 2A and 2B). A low level of PEEP (~5 cm H_2O) is usually applied to offset the reduction in functional residual capacity (FRC) with supine positioning in mechanically ventilated patients, whereas higher levels may be applied to improve oxygenation in patients with hypoxemic respiratory failure.

PEEP improves oxygenation primarily by changing the transmural pressure (Ptm) across the respiratory system. Also referred to as the distending or recoil pressure, Ptm is the pressure difference across the wall of a distensible structure and is determined by the difference between the pressure inside and outside of the structure. In the case of the respiratory system (i.e., the joined lungs and chest wall) the transmural pressure can represented as:

$$\mathrm{Ptm} = \mathrm{Palv} - \mathrm{Patm}, \qquad (1)$$

where Palv represents alveolar pressure and Patm represents atmospheric pressure. Because all pressures are referenced to

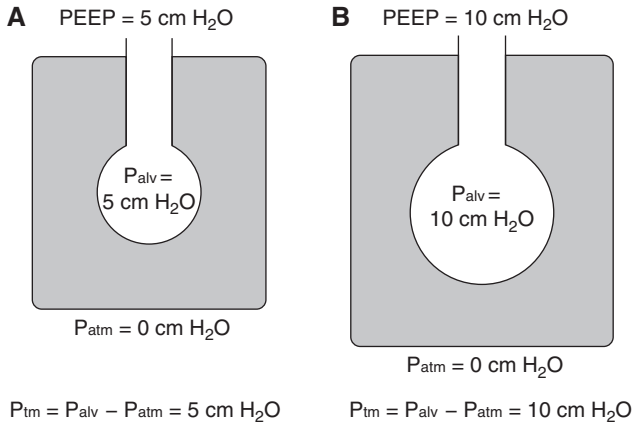

Figure 3. Schematic representation of the effect of an increase in PEEP from (*A*) 5 cm H_2O to (*B*) 10 cm H_2O on the transmural pressure (Ptm) and the volume of the respiratory system. As Ptm increases, the volume of the respiratory system increases in proportion to respiratory system compliance. Palv = alveolar pressure; Patm = atmospheric pressure; PEEP = positive end-expiratory pressure.

atmospheric pressure, Patm is considered to be 0 cm H_2O and Equation 1 can be rewritten as:

$$\text{Ptm} = \text{Palv} \qquad (2)$$

For a given compliance, higher Ptm leads to a greater volume of the distensible structure. When PEEP is applied or increased, Palv rises, leading to an increase in transmural pressure, which in turn increases the volume of the respiratory system (Figure 3). The net effect of these changes is to preserve ventilation of the alveolar unit, thereby maintaining an adequate ventilation–perfusion ratio and in turn efficient gas exchange.

The effects of PEEP on alveolar volume and oxygenation can be further appreciated by examining the volume–pressure relationship of the respiratory system during mechanical ventilation (Figure 4). At the end of exhalation, during either spontaneous breathing or mechanical ventilation, the respiratory system returns to FRC, the equilibrium position at which the inward recoil of the lung is exactly balanced by the outward recoil of the chest wall. When PEEP is 0 cm H_2O, Ptm is 0, and FRC is at the volume noted in Figure 4B. Increases in PEEP raise Ptm such that the equilibrium position is now at a higher volume, as shown in Figure 4C. The increase in end-expiratory volume prevents alveolar collapse on exhalation, thereby maintaining ventilation–perfusion ratios and improving oxygenation.

The volume–pressure relationship demonstrates another benefit of PEEP. The slope of the relationship represents the compliance of the respiratory system and is often decreased in diffuse alveolar filling diseases, such as ARDS, or by processes outside the lung parenchyma, such as abdominal compartment syndrome (Figure 4A). At both very low and high lung volumes, the compliance of the system is low (i.e., the curve is relatively flat) and large pressure changes are necessary to achieve a given change in volume. Within a certain range of volumes, however, the volume–pressure relationship is steep, and smaller pressure changes are needed to achieve the same change in volume. This high compliance region represents the optimal range of pressures and volumes over which to ventilate a patient. In the absence of PEEP, the respiratory system returns to the flat portion of the volume–pressure relationship at end-exhalation, where significant pressure changes are required to open alveoli with the subsequent breath (Figure 4B). Repetitive opening and closing of alveoli in this manner is thought to contribute to ongoing lung injury by a mechanism referred to as *atelectrauma*. By increasing alveolar volume at end-exhalation, PEEP ensures that the subsequent inhalation begins closer to the steeper portion of the volume–pressure relationship, where smaller pressure changes are necessary to achieve the desired change in volume (Figure 4C). Ventilating the respiratory system in this region of higher compliance helps avoid further lung injury.

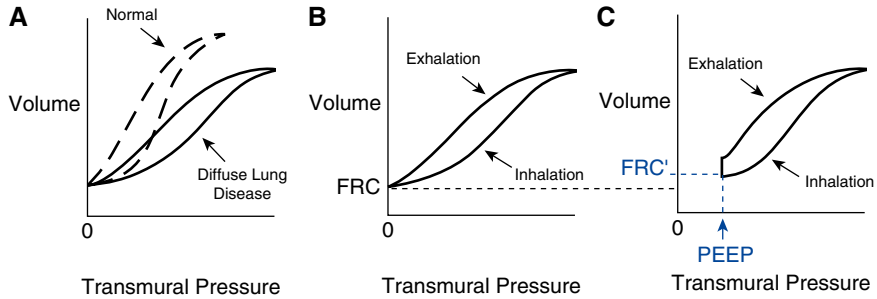

Figure 4. The relationship between respiratory system transmural pressure and volume in (*A*) a healthy subject and (*A–C*) in a patient with diffuse alveolar filling and reduced compliance. By increasing end-expiratory volume (FRC′), PEEP reduces alveolar collapse during expiration and ensures that each inhalation begins from the steeper, more compliant region of the pressure volume relationship. FRC = functional residual capacity; PEEP = positive end-expiratory pressure.

Why Higher PEEP Worsened Hypoxemia, Blood Pressure, and Central Venous Oxygen Saturation in This Patient

The worsening of this patient's hypoxemia, hypotension, and central venous oxygen saturation on higher levels of PEEP can be explained by two factors: (*1*) anatomic and physiological features of the pulmonary microcirculation that affect the usefulness of PEEP in focal lung processes and (*2*) adverse effects of PEEP on cardiac output and systemic oxygen delivery.

PEEP and focal lung processes. The pulmonary microcirculation is composed of two types of vessels—intraalveolar vessels that travel within the walls of the alveoli

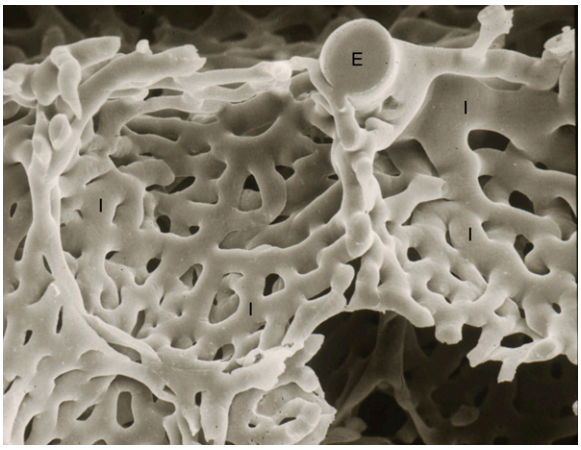

Figure 5. A scanning electron micrograph demonstrating the pulmonary microcirculation at the alveolar level, including extraalveolar vessels (*E*) and intraalveolar vessels (*I*). Image source: Guntheroth WG, Luchtel DL, Kawabori I. Pulmonary microcirculation: tubules rather than sheet and post. *J Appl Physiol Respir Environ Exerc Physiol* 1982:53:510–515. Reprinted by permission.

and participate in gas exchange, and extraalveolar vessels residing within the interstitium that carry blood to and from the intraalveolar vessels (Figure 5). These vessels respond differently to changes in lung volume. Extraalveolar vessels have small diameters and high resistance at low lung volumes (Figure 6A) but larger diameters and lower resistance at higher volumes when the vessels are tethered open by the surrounding alveoli (Figure 6B). In contrast, intraalveolar vessels have larger diameters and lower resistance at low volumes (Figure 6A) but smaller diameters and higher resistance at higher lung volumes (Figure 6B). Because the extra- and intraalveolar vessels are in series, the total pulmonary vascular resistance associated with these vessels is determined by the sum of the resistance of each class of vessels. As a consequence, total pulmonary vascular resistance is high at the extremes of lung volume (residual volume and total lung capacity) and lowest at functional residual capacity (Figure 7).

The different behavior of these vessels with changes in lung volume partly explains why increased PEEP worsened hypoxemia in this patient. In the case of a lobar pneumonia, the diseased portion of the lung has low compliance relative to the normal areas of lung parenchyma. As a result, increased PEEP results in larger volume changes in healthy, more compliant areas of lung than in the area affected by the pneumonia. As healthy alveoli are overdistended, intraalveolar vessels are stretched like an elastic band and their diameters decrease significantly (Figure 6B). This leads to an increase in resistance associated with these vessels that is not balanced by the decrease in resistance associated with extraalveolar vessels. Because they comprise the walls of the alveoli, intraalveolar vessels are also subject to the effects of alveolar pressure. Large increases in alveolar pressure with high PEEP decrease transmural pressure across the capillary walls and decrease their diameter. As a result, total vascular resistance in these lung regions increases and blood flow is diverted to areas of lower resistance, including areas of diseased lung where compliance is lower and significant changes in alveolar volume and vascular resistance do not occur. This increase in flow may be enough to overcome the effects of any hypoxic pulmonary vasoconstriction

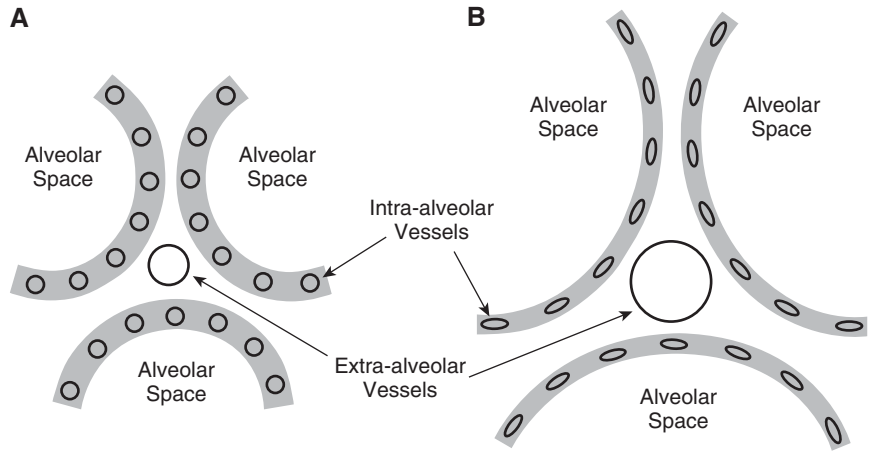

Figure 6. Alveolar and extraalveolar vessels at low and high volumes. (*A*) Near the equilibrium volume of the respiratory system, intraalveolar vessels reach their largest diameter and have relatively low resistance. (*B*) At high lung volumes, intraalveolar vessels are compressed and elongated by alveolar distention, and resistance rises. The resistance of extraalveolar vessels falls as they are tethered open by the surrounding lung parenchyma.

that may have occurred in response to the pneumonia. Diversion of blood flow to these areas lowers ventilation–perfusion ratios and increases the flow through shunt units, thereby worsening gas exchange.

Adverse effects on systemic oxygen delivery and venous oxygen content. Another factor in the patient's worsening arterial oxygenation was the decline in systemic oxygen delivery on the higher PEEP. Oxygen delivery ($\dot{D}_{O_2}$) is a function of both cardiac output ($\dot{Q}$) and arterial oxygen content (Ca_{O_2}):

$$\dot{D}_{O_2} = \dot{Q} \times Ca_{o_2}, \qquad (3)$$

where oxygen content is determined by hemoglobin concentration ([Hb]), arterial oxygen saturation (Sa_{O_2}), and Pa_{O_2} as represented below:

$$Ca_{o_2} = (1.34 \times [Hb] \times Sa_{o_2}/100) + (0.003 \times Pa_{o_2}) \qquad (4)$$

Depending on the compliance of the lung parenchyma, high levels of PEEP increase intrathoracic pressure. This raises right atrial pressure and reduces the pressure gradient driving venous return to the heart, which in turn decreases systemic venous return and ventricular preload. If the reflex increase in heart rate is unable to compensate for this phenomenon, which is worse when PEEP is applied in focal processes and in patients with preexisting volume depletion, cardiac output falls and

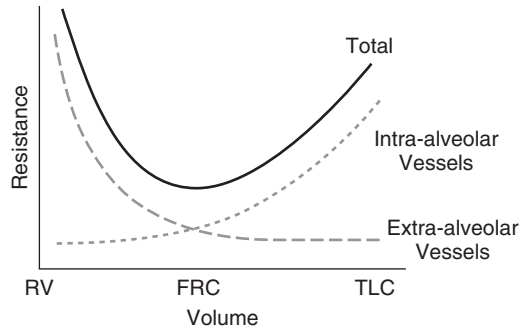

Figure 7. Pulmonary vascular resistance as a function of lung volume. Total pulmonary vascular resistance (*solid line*) is the sum of the resistance of intraalveolar and extraalveolar vessels (*dashed lines*). Total resistance is high at residual volume (RV) and total lung capacity (TLC) and lowest at functional residual capacity (FRC).

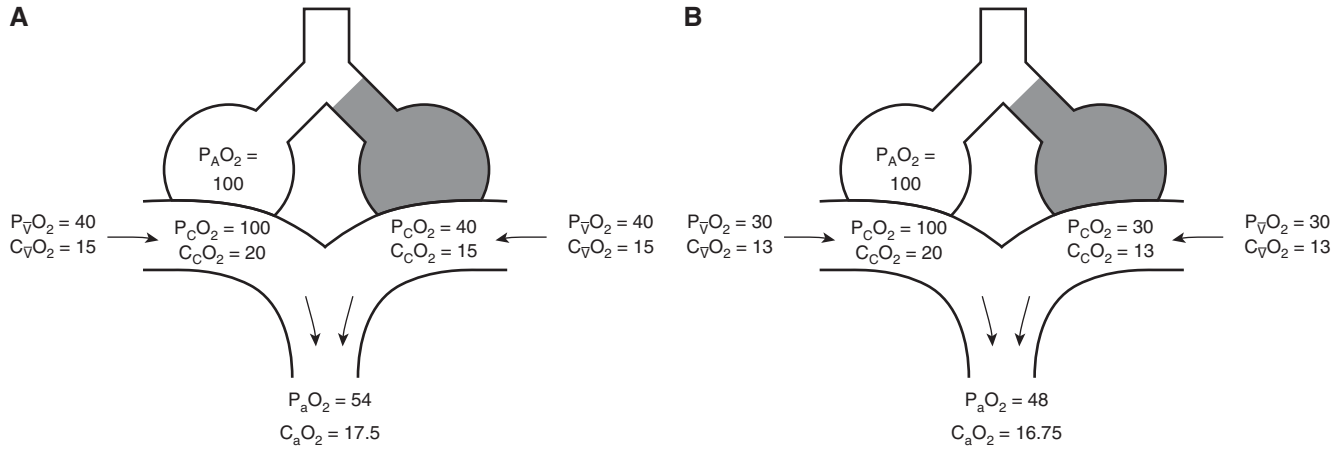

Figure 8. The effect of decreased mixed venous oxygen content on arterial oxygenation. A two-compartment model illustrates the effect of a 50% shunt on Pa_{O_2} and arterial oxygen content (Ca_{O_2}) when mixed venous content ($C\bar{v}_{O_2}$) decreases from 15 ml O_2/100 ml blood to 13 ml O_2/100 ml blood. Hemoglobin concentration is assumed to be 15 g/dl. Because blood flow is equally distributed, Ca_{O_2} is equal to the mean content of the blood leaving each compartment. Pa_{O_2} is determined from the hemoglobin–O_2 dissociation curve and does not represent the average of the partial pressure in each compartment. Note that Ca_{O_2} decreases even though there has been no change in ventilation–perfusion relationships. A corresponding decrease would be seen in arterial oxygen saturation (Sa_{O_2}), which is not depicted in this figure. Cc_{O2} = capillary oxygen content; PA_{O_2} = alveolar partial pressure of oxygen; Pc_{O_2} = capillary partial pressure of oxygen; $P\bar{v}_{O_2}$ = mixed venous partial pressure of oxygen.

systemic hypotension may ensue. More importantly, even though Pa_{O_2}, Sa_{O_2}, and Ca_{O_2} may increase with higher PEEP, overall oxygen delivery may decrease depending on the magnitude of the decrease in cardiac output. The tissues respond to the decrease in oxygen delivery by increasing oxygen extraction, which lowers the P_{O_2} of the blood leaving the tissues and in turn decreases the oxygen content and saturation of both central venous and mixed venous blood. Although cardiac output was not measured in this patient, the fall in Scv_{O_2} with increased PEEP is highly suggestive of her having decreased cardiac output and tissue oxygen delivery in response to that intervention.

The decline in central and mixed venous content and saturation contributes to worsening hypoxemia in patients with increased shunt fractions. In shunt regions of the lung, blood exiting the pulmonary capillaries has the same P_{O_2}, oxygen content, and oxygen saturation as mixed venous blood that entered those capillaries, as no gas exchange occurs across the alveolar–capillary membrane (Figure 8A). Any decrease in mixed venous oxygen content leads to a decrease in oxygen content and saturation of blood leaving the pulmonary capillaries. When mixing of blood from these and other regions of the lung occurs in the pulmonary veins and left atrium, Ca_{O_2} and Sa_{O_2} decrease as well (Figure 8B). Interventions that improve tissue oxygen delivery, such as the use of dobutamine to improve cardiac output, counteract this phenomenon by decreasing tissue oxygen extraction and raising venous oxygen content.

Summary

PEEP has an important role in the management of patients with hypoxemic respiratory failure, especially in patients with high shunt fractions who are less responsive to increases in $F_{I_{O_2}}$, but it may also have adverse effects. Although PEEP improves oxygenation in diffuse lung disease, it can paradoxically worsen ventilation–perfusion ratios and gas exchange in patients with more focal processes. In addition, high levels of PEEP can decrease cardiac output and tissue oxygen delivery with subsequent decreases in mixed and central venous oxygen content that contribute to impaired arterial oxygenation in patients with increased shunt fractions. ■

Author disclosures are available with the text of this article at www.atsjournals.org.

Recommended Reading

Fougères E, Teboul JL, Richard C, Osman D, Chemla D, Monnet X. Hemodynamic impact of a positive end-expiratory pressure setting in acute respiratory distress syndrome: importance of the volume status. *Crit Care Med* 2010;38:802–807.

Gattinoni L, Protti A, Caironi P, Carlesso E. Ventilator-induced lung injury: the anatomical and physiological framework. *Crit Care Med* 2010;38 (10, Suppl):S539–S548.

Jardin F, Farcot JC, Boisante L, Curien N, Margairaz A, Bourdarias JP. Influence of positive end-expiratory pressure on left ventricular performance. *N Engl J Med* 1981;304: 387–392.

Kacmarek RM, Pierson DJ, editors. AARC conference on positive end-expiratory pressure. *Respir Care* 1988;33:419–527.

Luce JM. The cardiovascular effects of mechanical ventilation and positive end-expiratory pressure. *JAMA* 1984;252:807–811.

Lutch JS, Murray JF. Continuous positive-pressure ventilation: effects on systemic oxygen transport and tissue oxygenation. *Ann Intern Med* 1972;76:193–202.

Walley KR. Use of central venous oxygen saturation to guide therapy. *Am J Respir Crit Care Med* 2011;184:514–520.